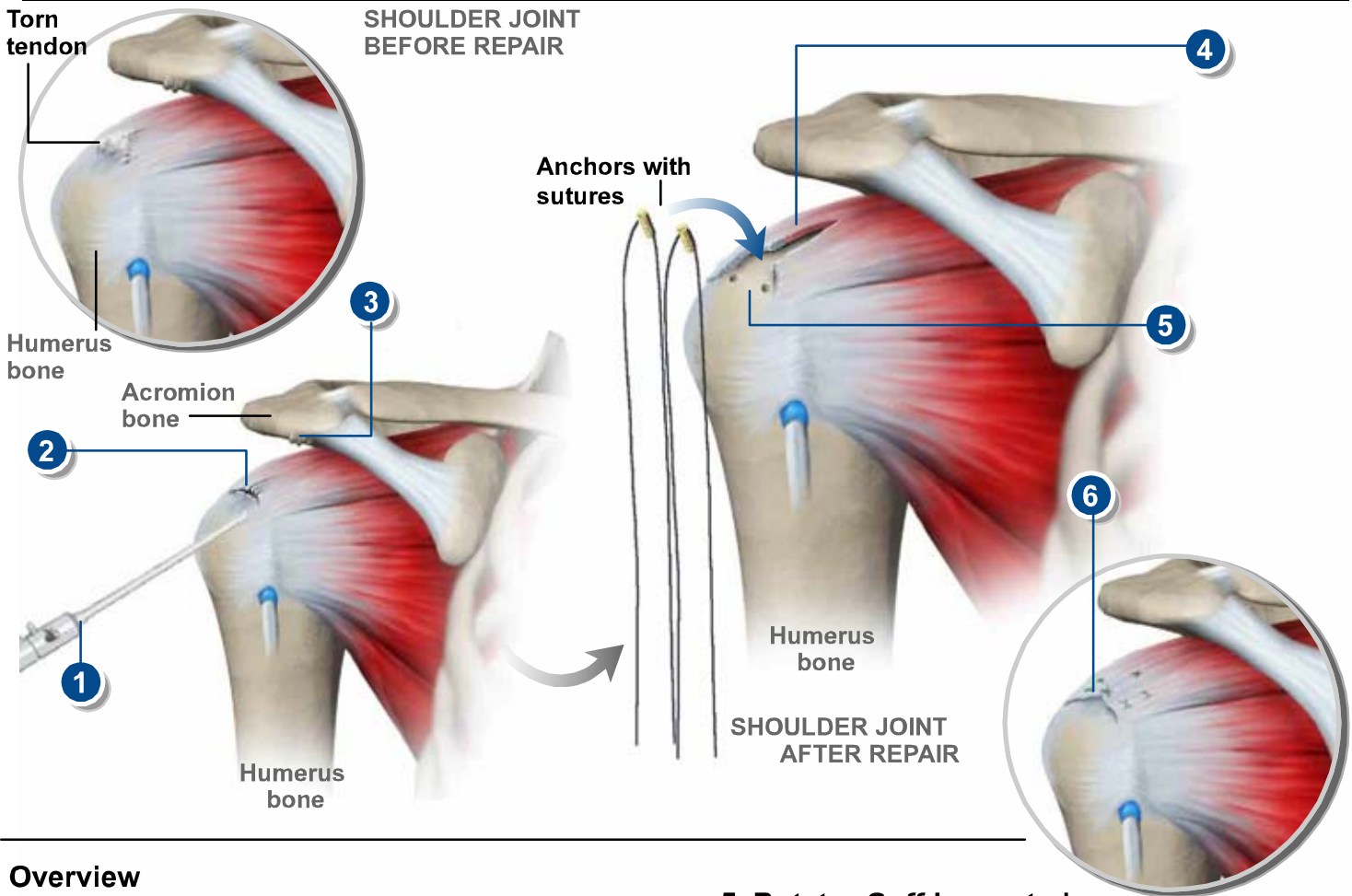


ARTHROSCOPIC ROTATOR CUFF REPAIR



Overview

This surgical procedure is used to inspect and reattach torn tendons in the shoulder's rotator cuff. The initial part of the surgery is performed arthroscopically through small tubes. In some cases, open surgery may be needed to repair large tears.

1. Joint Inspected

The surgeon inserts a small video camera called an arthroscope through tiny incisions in the shoulder to inspect the damaged joint.

2. Joint Debrided

The surgeon removes any loose fragments of tendon or other debris from the damaged cuff tendon in the joint. This procedure, called debridement, is usually performed arthroscopically. Afterwards, the surgeon inspects the tissue damage in the joint and determines if more surgery is needed.

3. Acromion Smoothed

If bone spurs have formed on the bottom of the acromion, the surgeon uses a rasp-like tool to smooth the area. This is called subacromial decompression, or smoothing, and will keep the acromion from pinching down on the supraspinatus tendon. It is usually done arthroscopically.

5. Rotator Cuff Inspected

If no tear is found in the rotator cuff area, the procedure may end here. If the surgeon finds a torn rotator cuff tendon, the type of repair needed is based on the size and severity of the tear. Small to moderate tears may be repaired arthroscopically. Open surgery may be needed to repair large tears. First, the torn end of the tendon is cleaned up. Next, an area on the humerus is cleared.

5. Anchors Placed

The surgeon uses a drill or sharp tool to create one or more small holes in the bone. Anchors are then placed into the holes. The anchors hold stitches in place on the arm bone.

6. Tendon Sutured

The tear in the tendon is stitched together. The sutures are pulled tightly against the anchors, reattaching the tendon to the humerus.

End of Procedure

After surgery, the arm is usually placed in a sling. Physical therapy will be needed to regain full range of motion and increased shoulder strength. Over time, the tendon will naturally reattach itself to the humerus bone.